



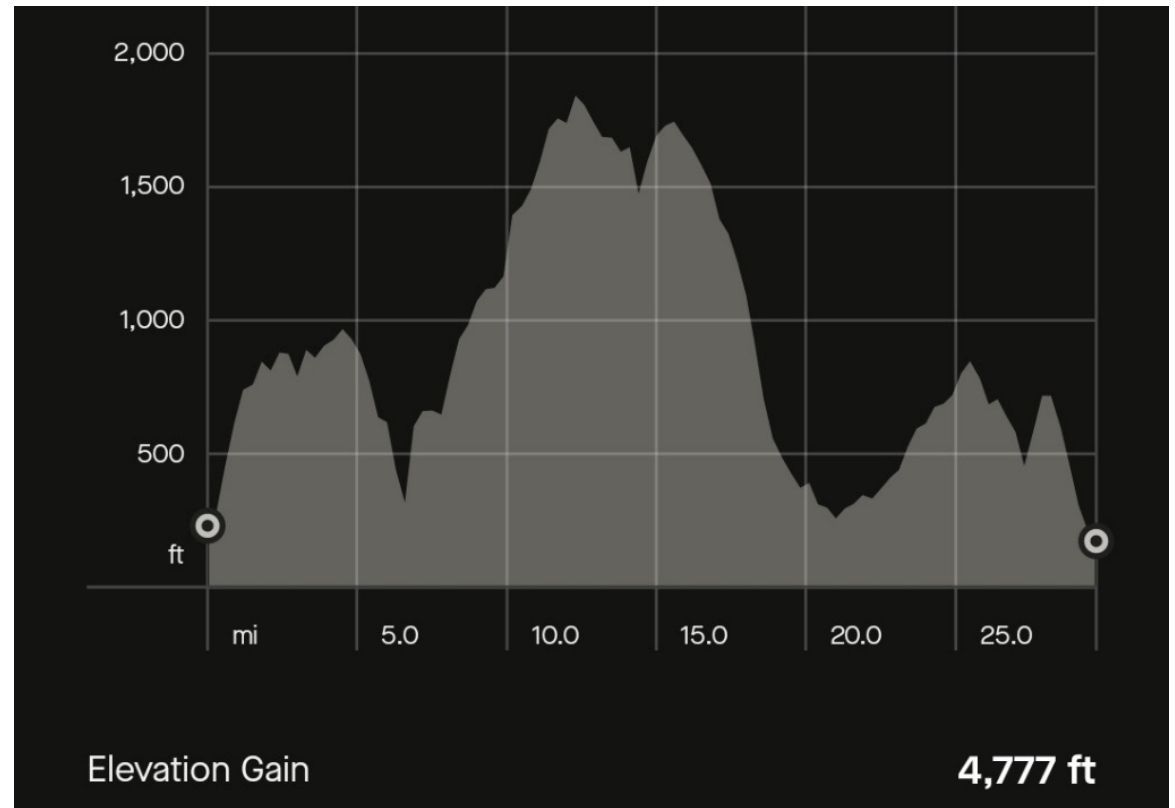Mersey and West Lancashire
Teaching Hospitals
NHS Trust

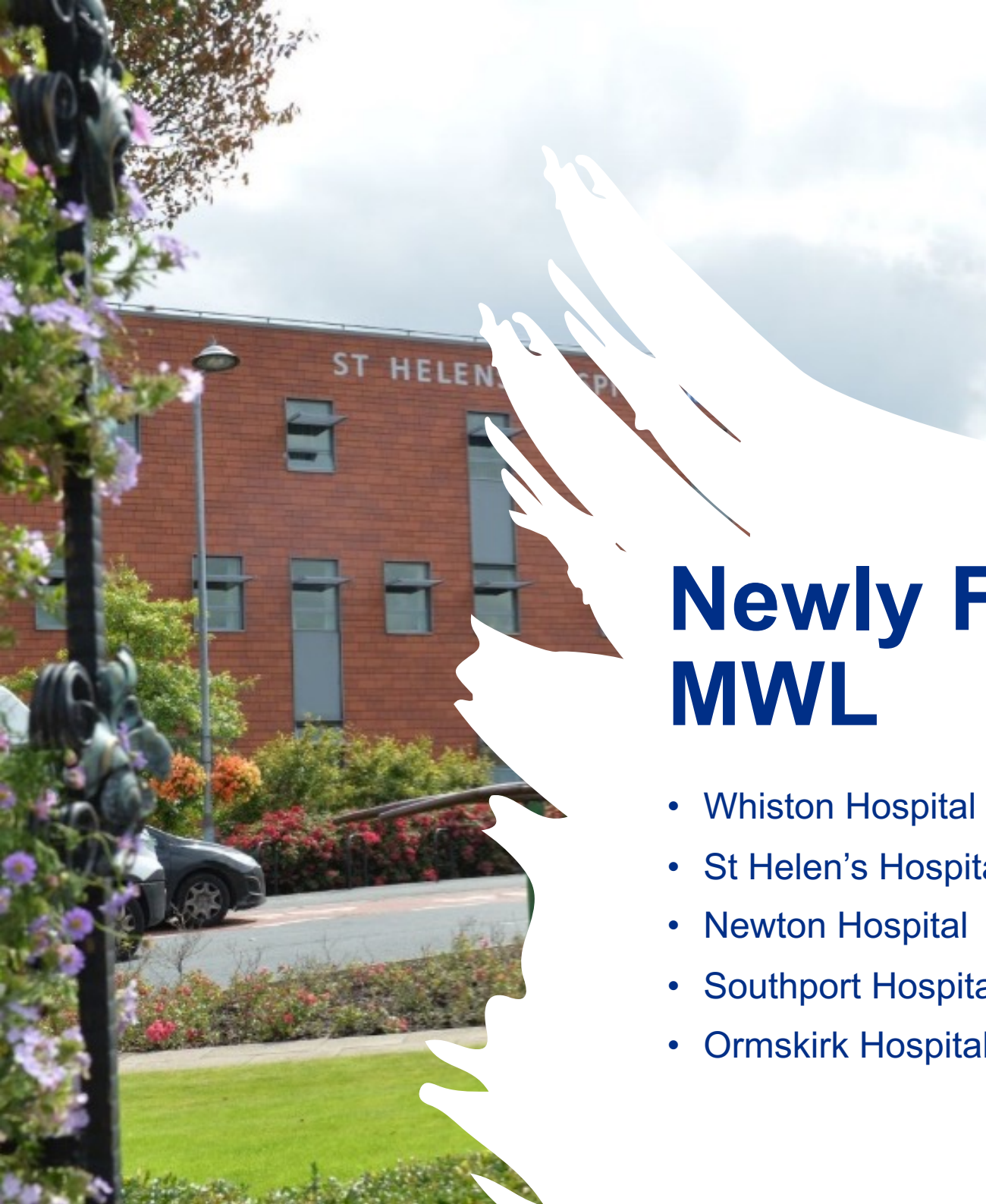Photos of diabetic problems within the human body

Helen Seddon
Medical Photographer

Who am I

- PG Cert Clinical Photography
- BA Hons Business Management (Executive) in Health and Social care
- IMI
- ACHS
- CMI





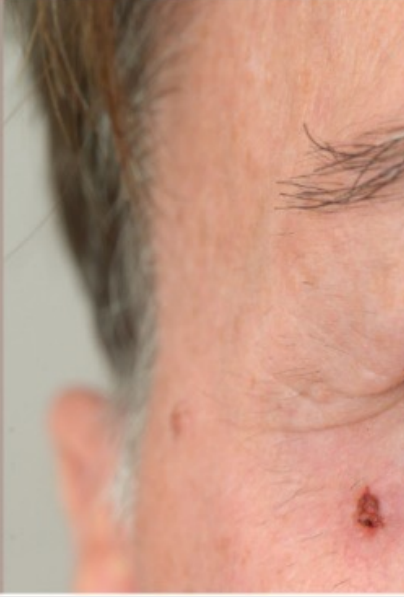
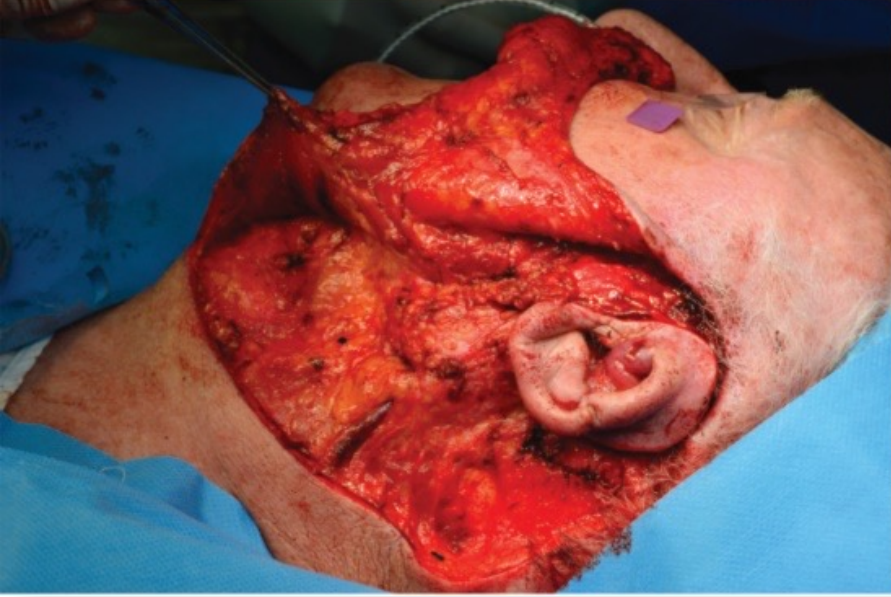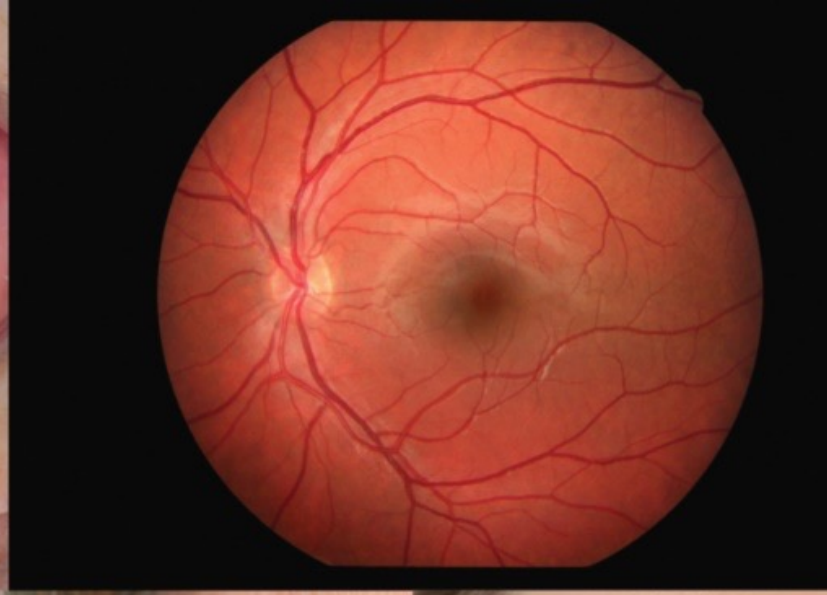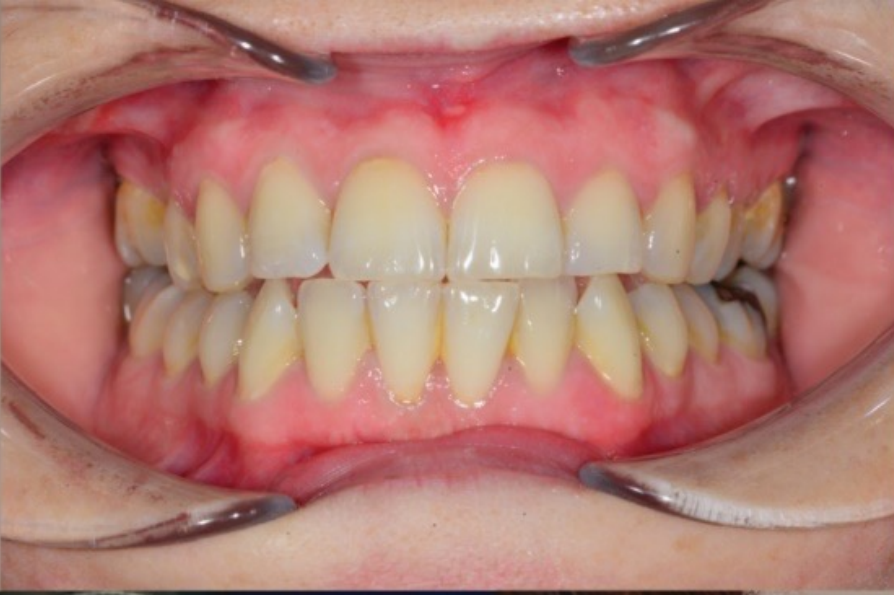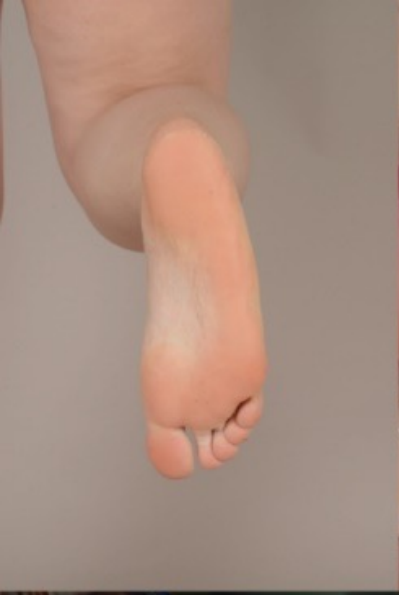Newly Formed MWL

- Whiston Hospital
- St Helen's Hospital
- Newton Hospital
- Southport Hospital
- Ormskirk Hospital

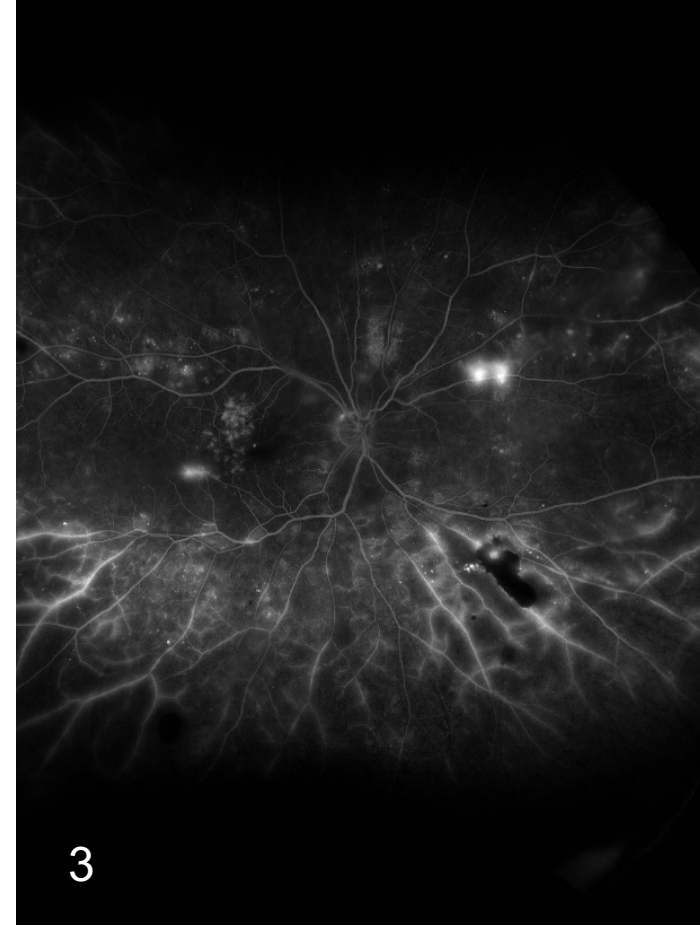
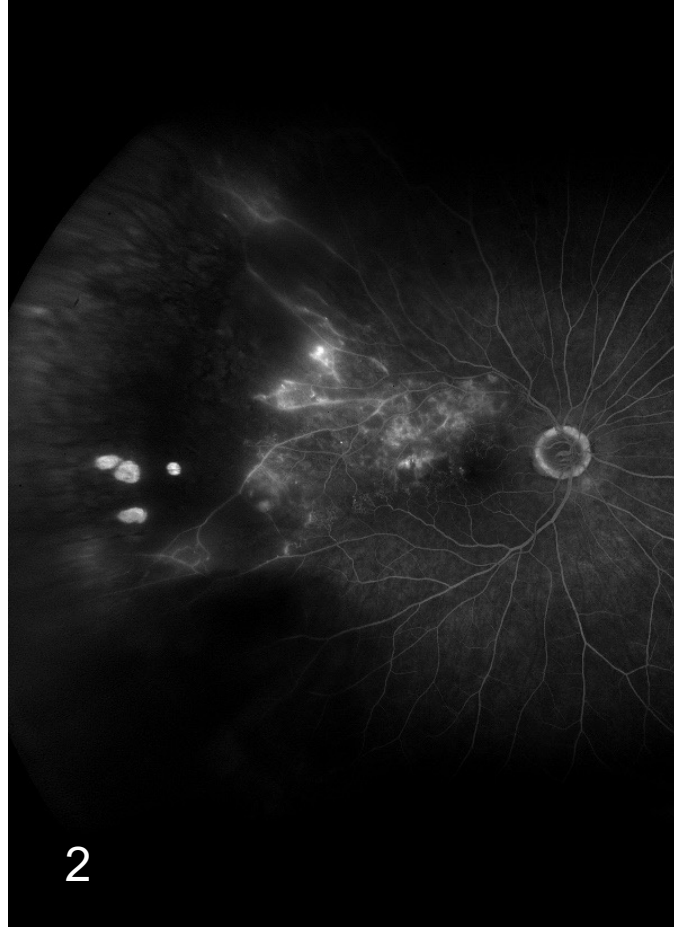
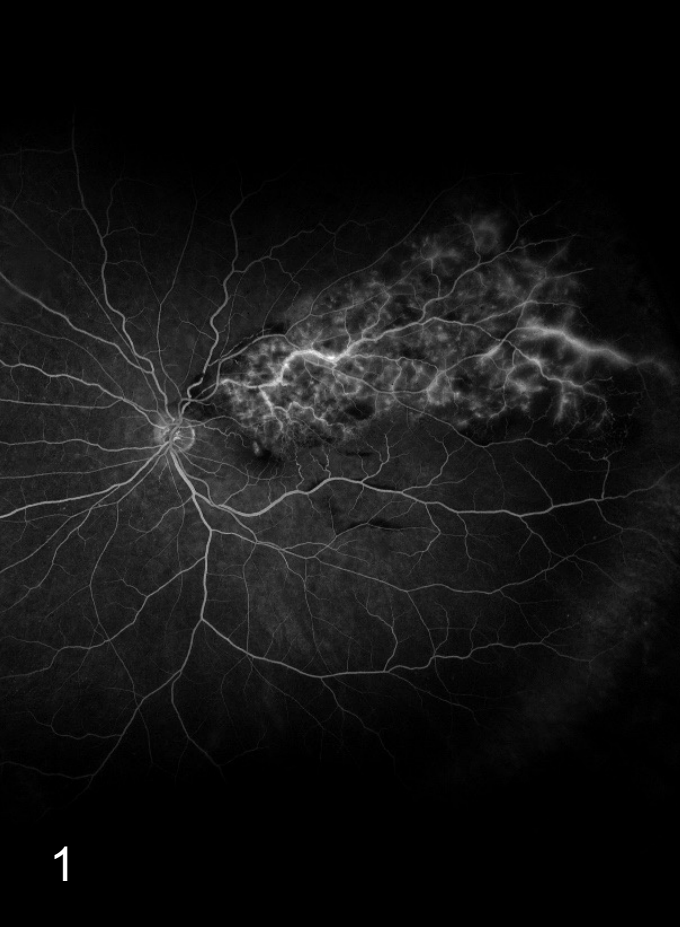Medical Photography @MWL

- 6.5 million patients
- Services include:
 - Acute Care
 - Primary Care
 - Community Services
 - Specialist Regional Services





Medical Photography @ MWL

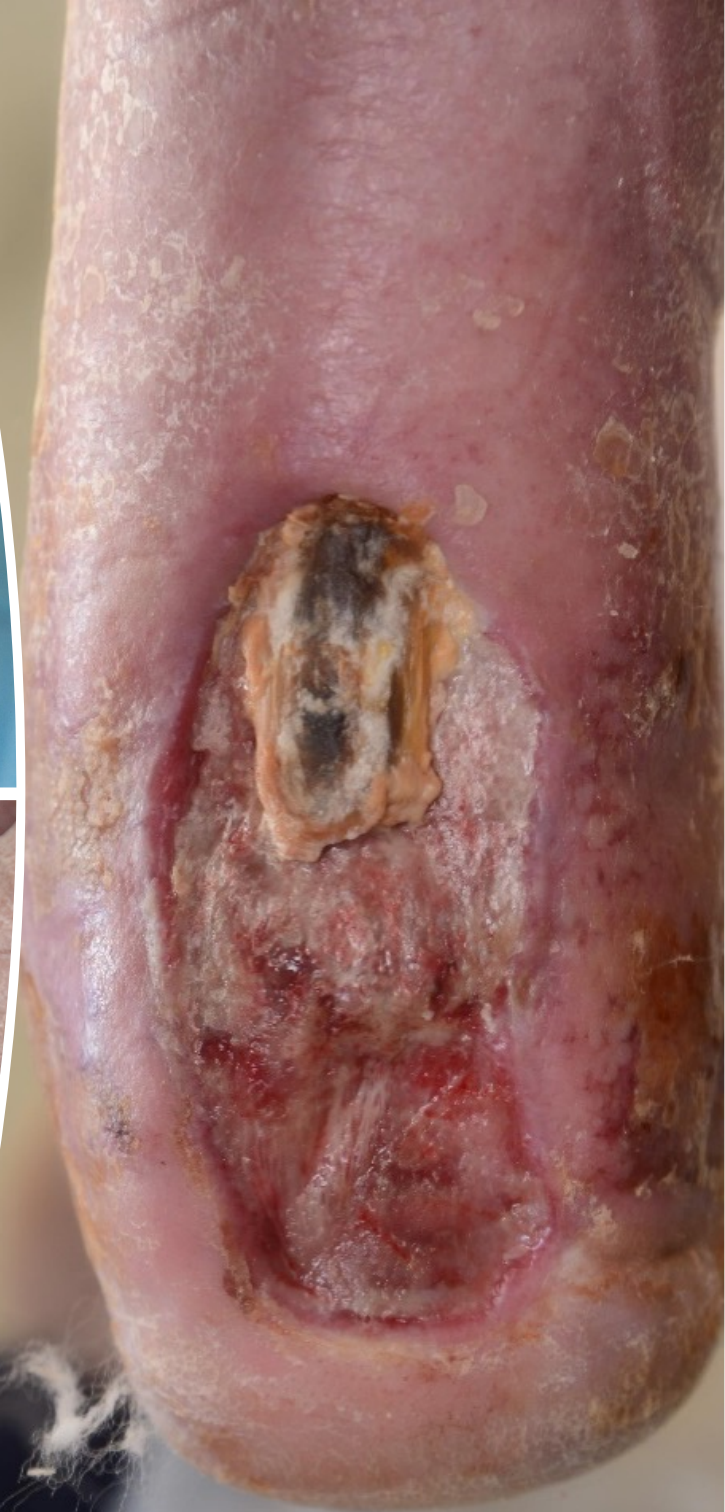
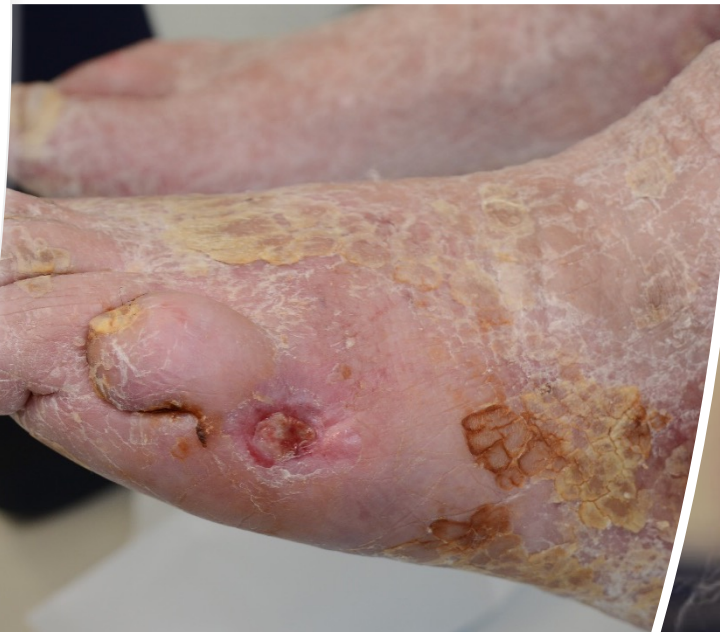
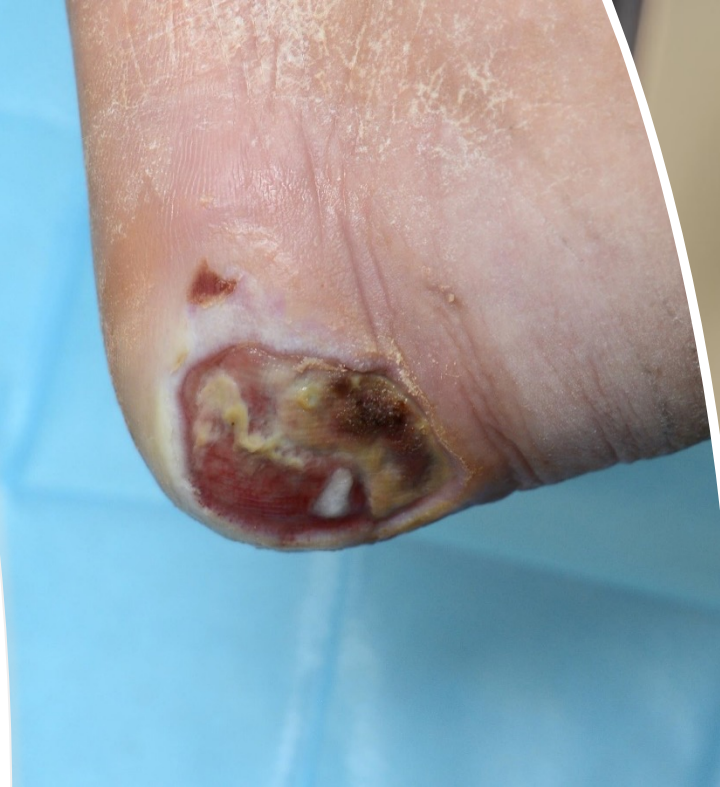Medical Photography Rennie Eye Clinic

- The Eye Clinic Provides a range of Specialist Ophthalmic Clinics which includes:
- Glaucoma
- Diabetic Retinopathy
- Macular Degeneration
- Laser
- Triage
- Botox
- Oculoplastic
- Ocular Motility
- Retinal

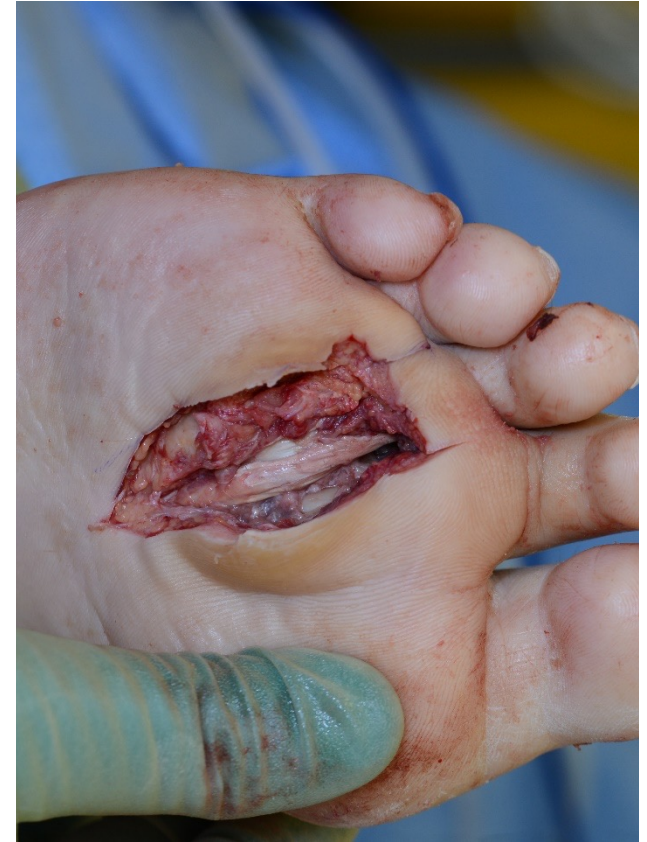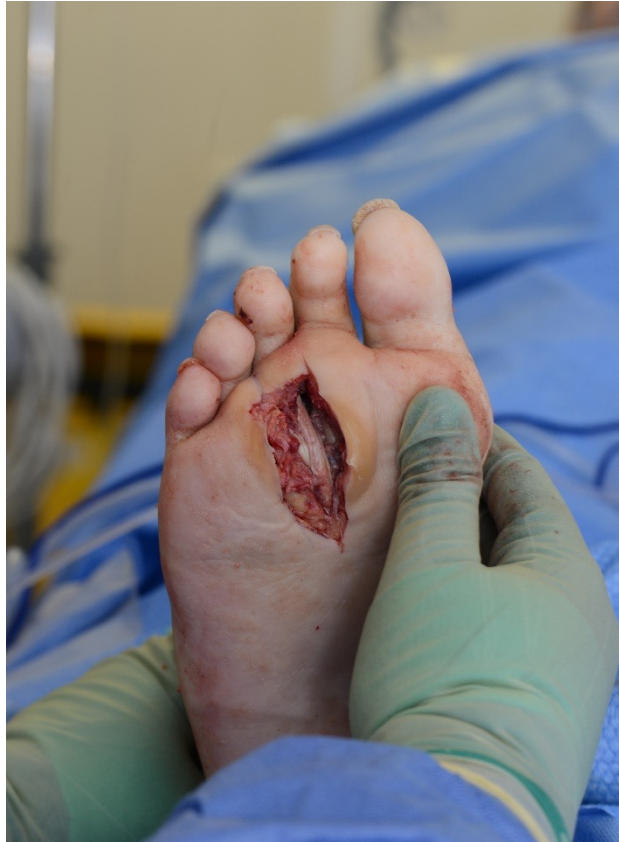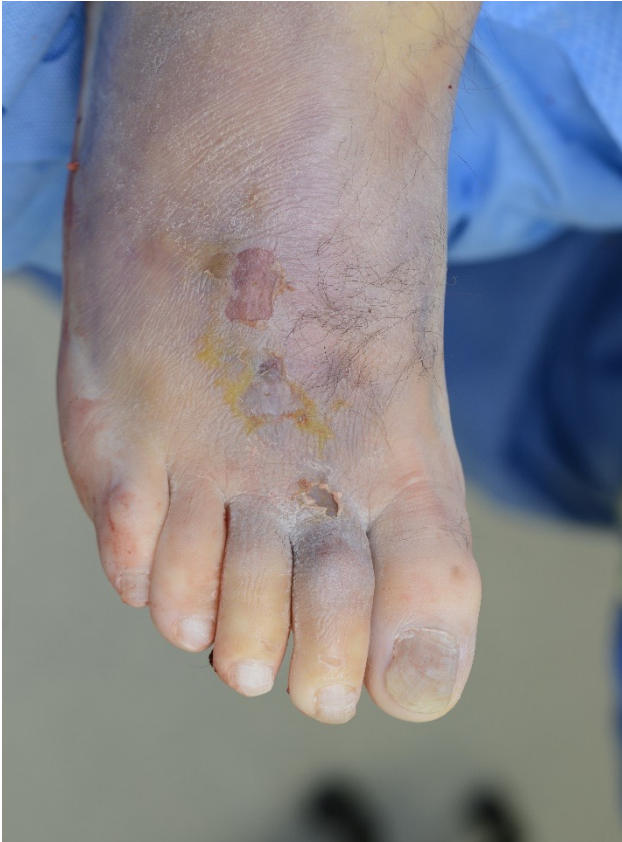The Diabetic Foot

- Raised glucose levels can damage the sensation in the feet
- Can affect the blood circulation, leading to less blood supply
- Restricted blood supply – problems with cuts and sores not healing
- If left untreated can lead to ulcers, infections and at worst amputations
- This is why good regular footcare plays an important role in diabetic care.



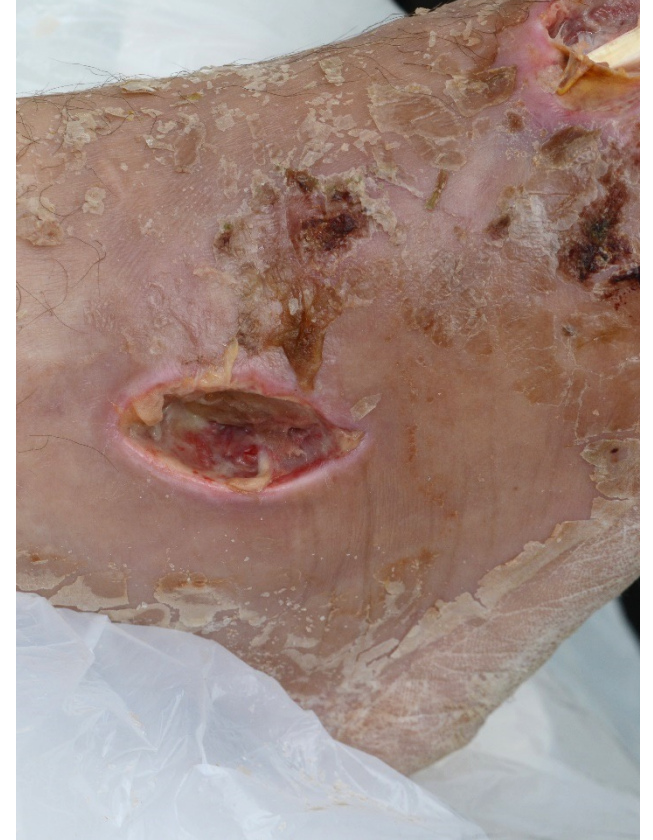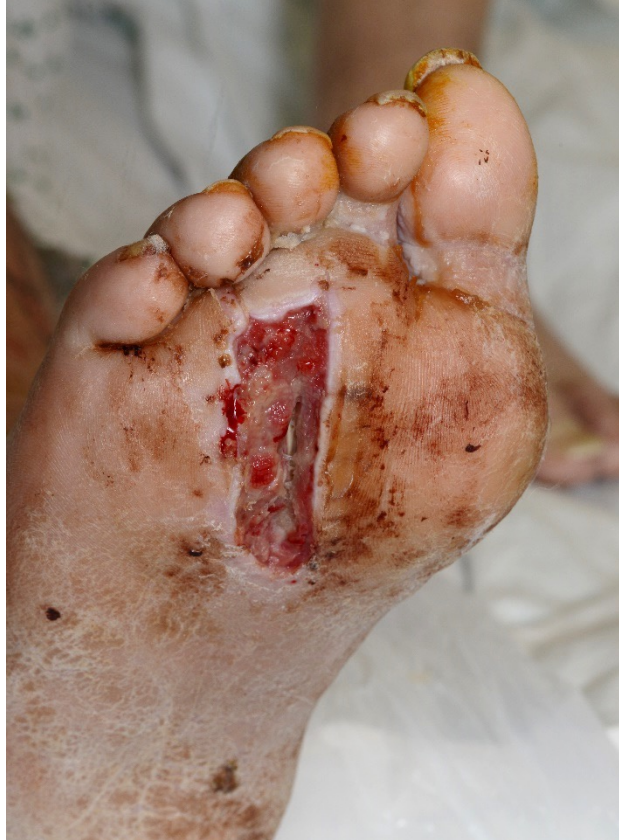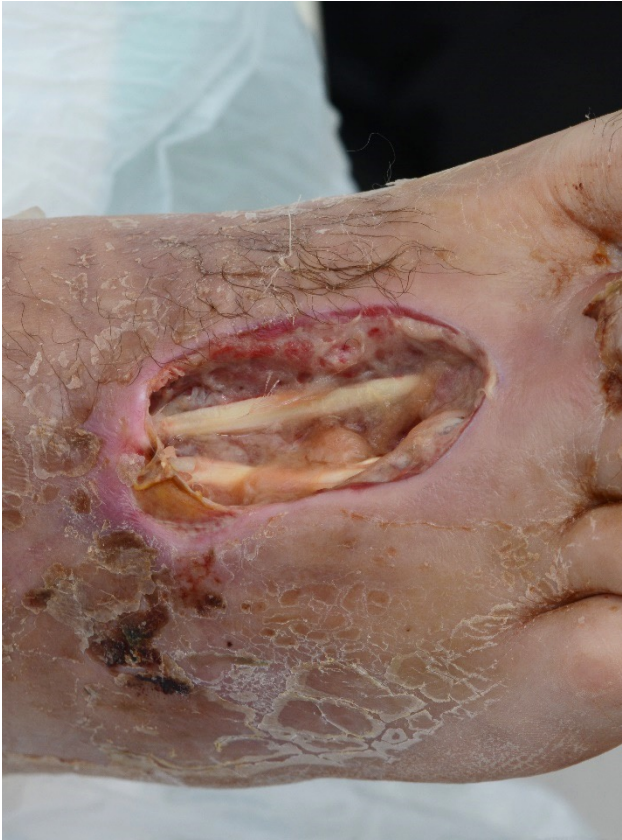The Diabetic foot

- 49yr male
- Infected ulcer
- 12th Dec



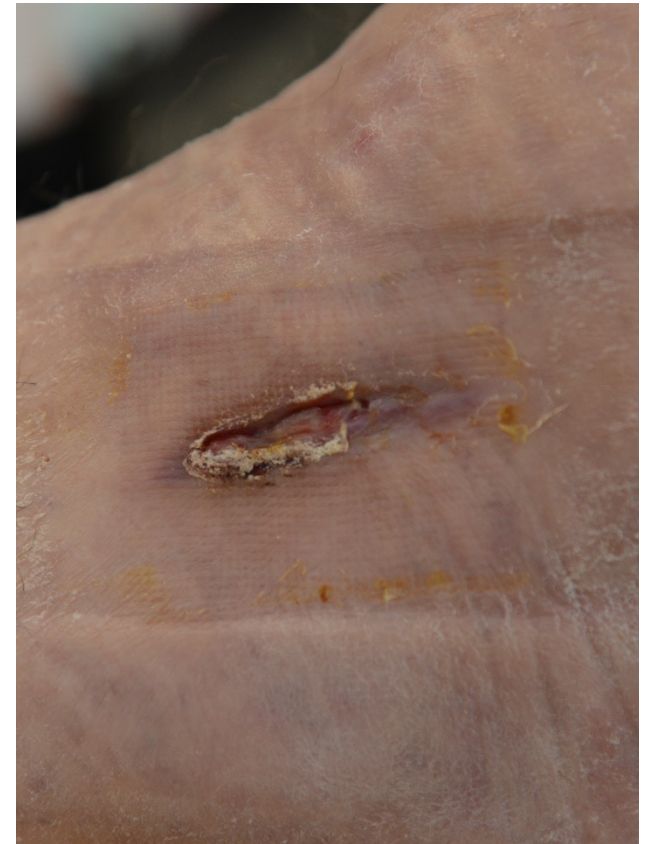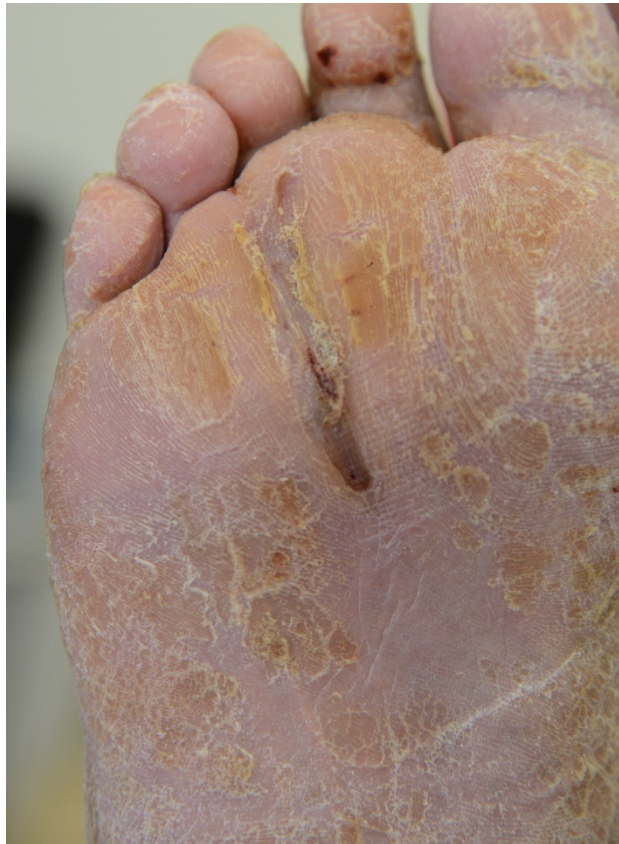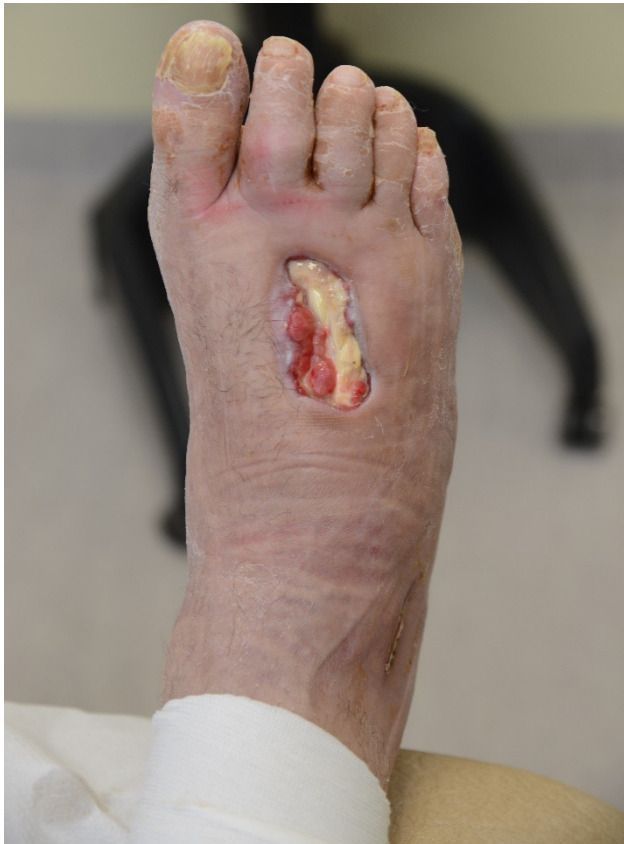The Diabetic Foot

- 49yr male
- Infected ulcer
- 31stth Dec



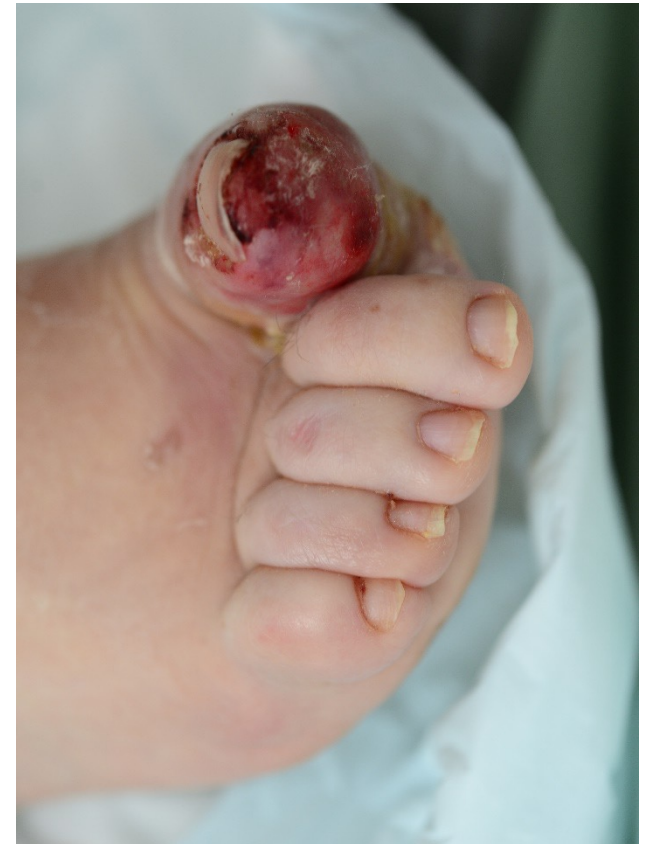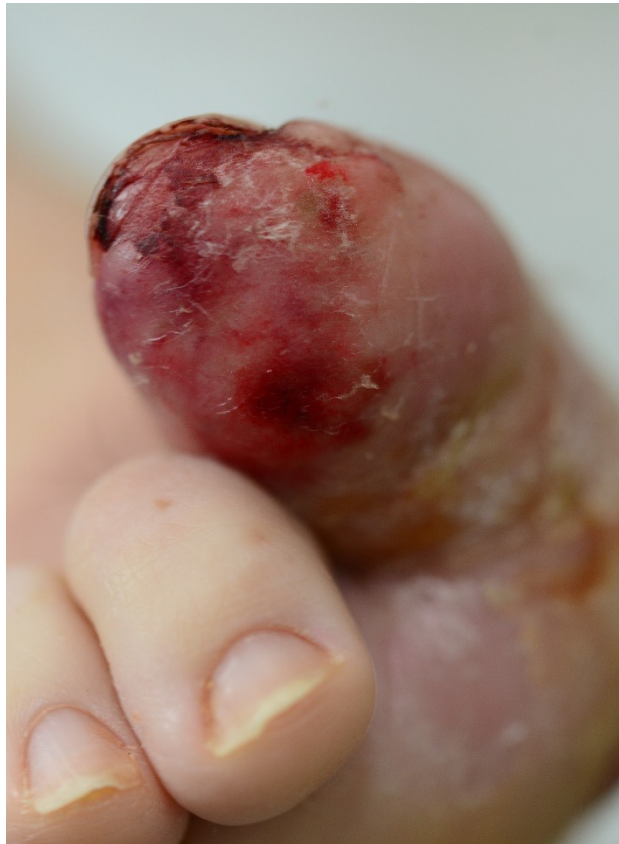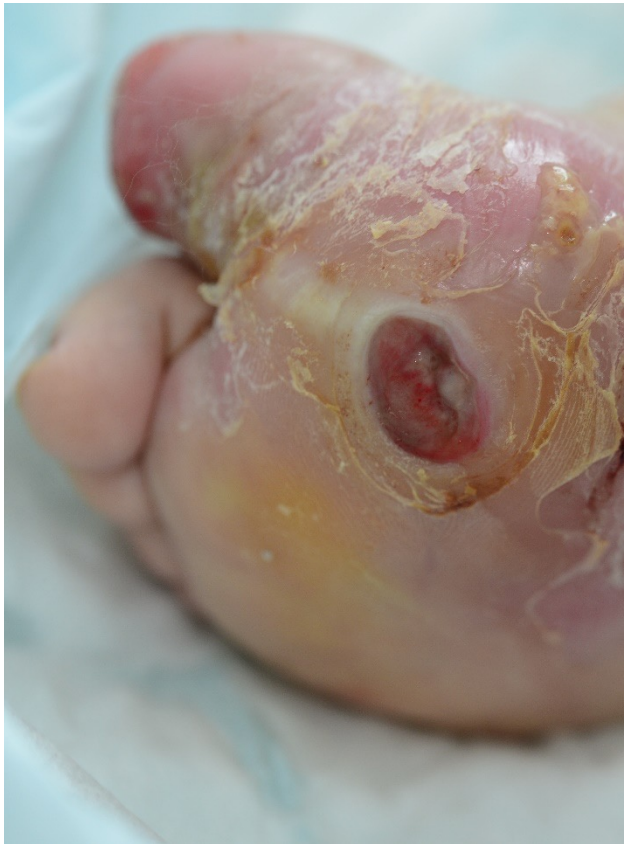The Diabetic Foot

- 49yr male
- Infected ulcer
- 11th Feb



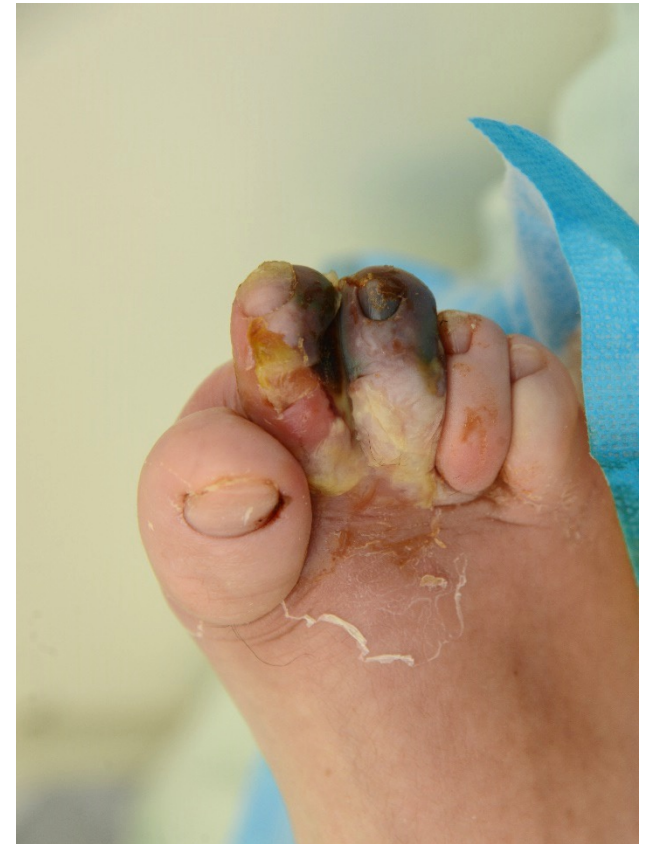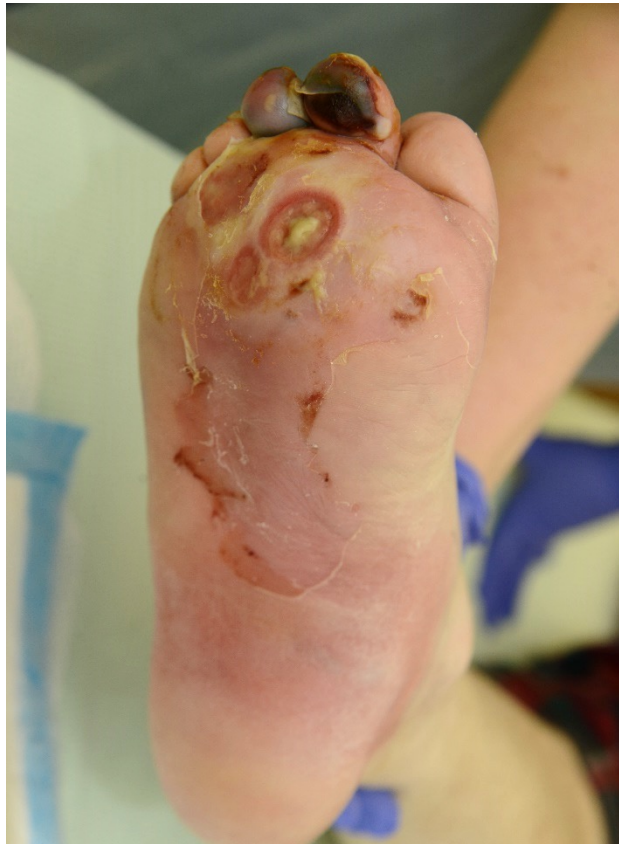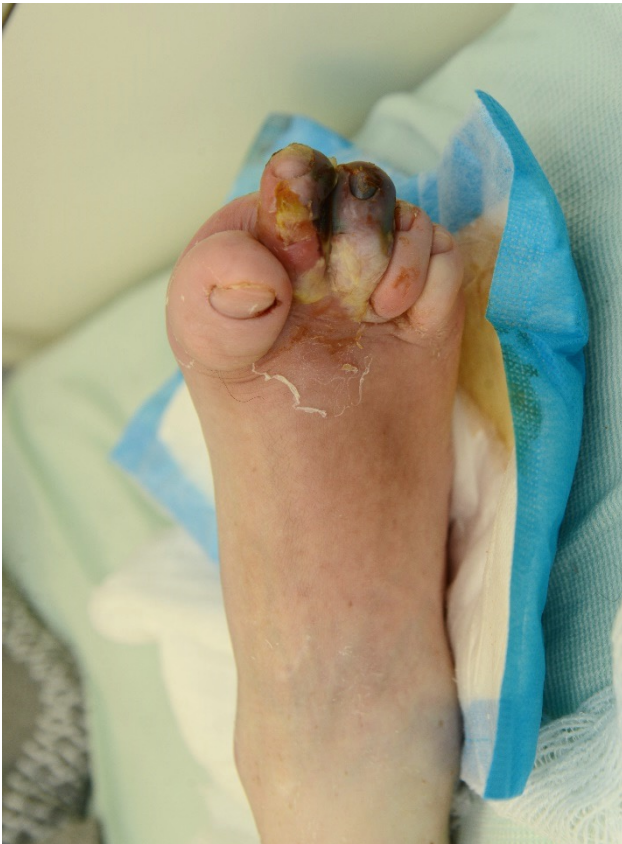The Diabetic Foot

- 51 yr male
- 21 yr known history of type 2
- 16th June



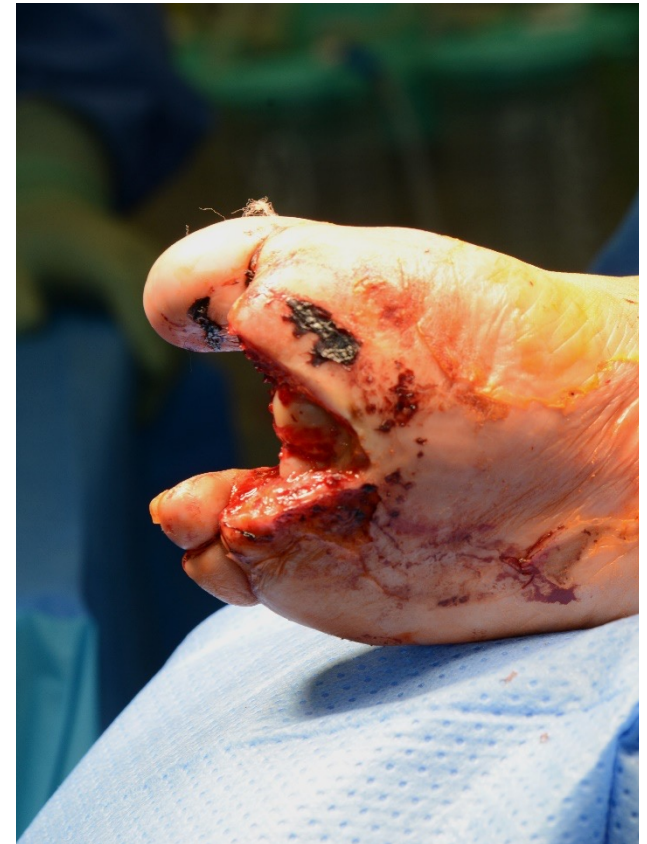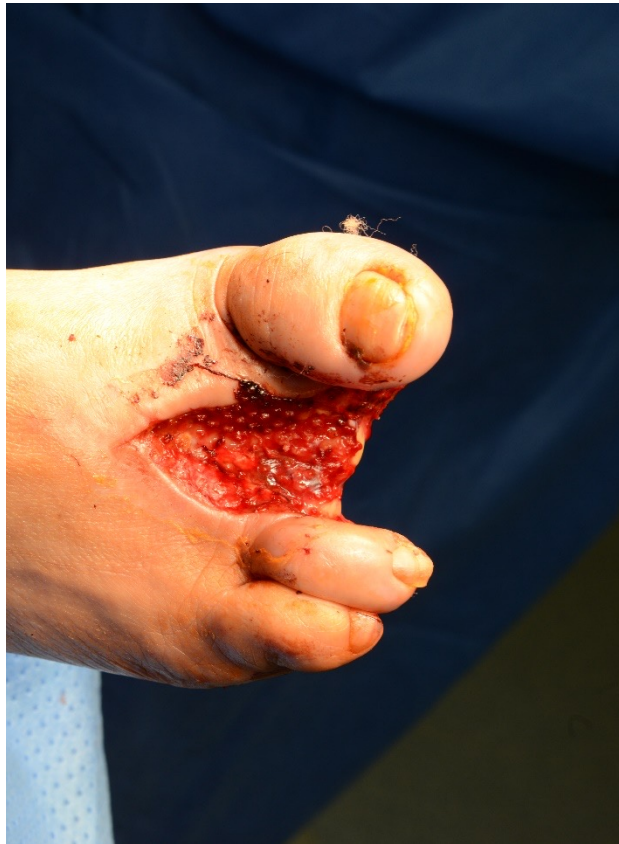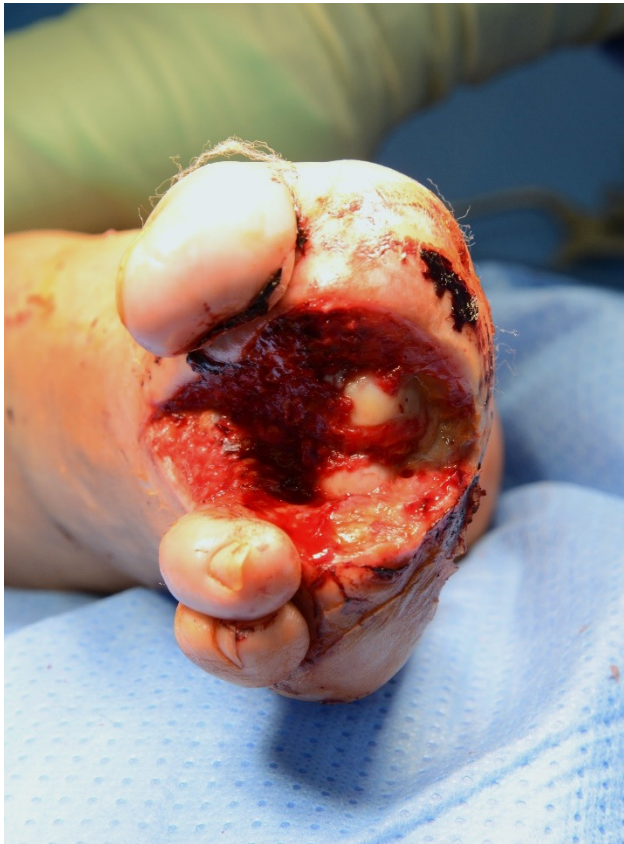The Diabetic foot

- 51 yr male
- 21 yr known history of type 2
- 15th Dec



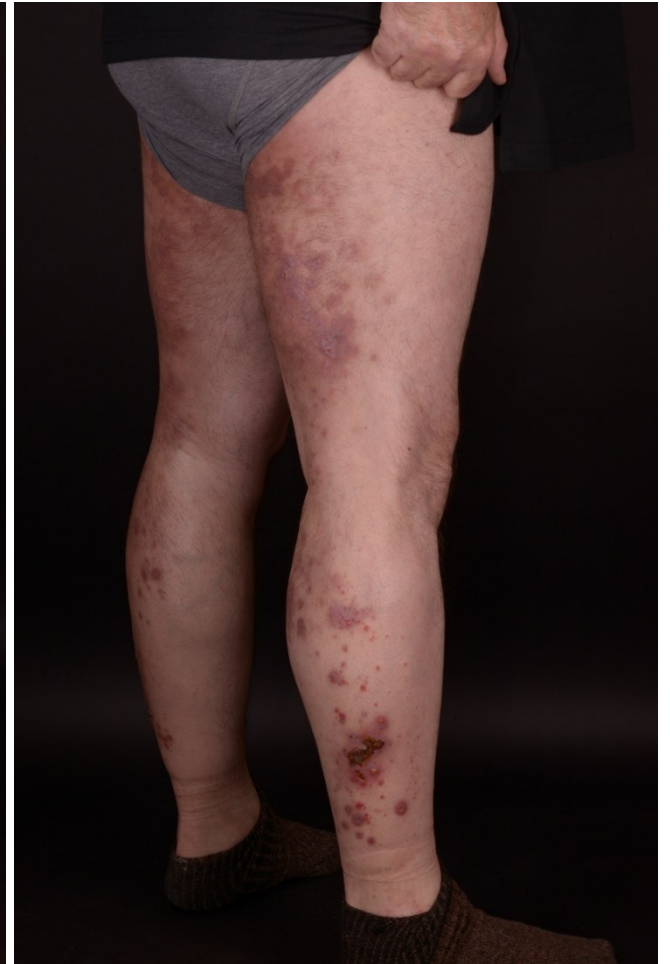
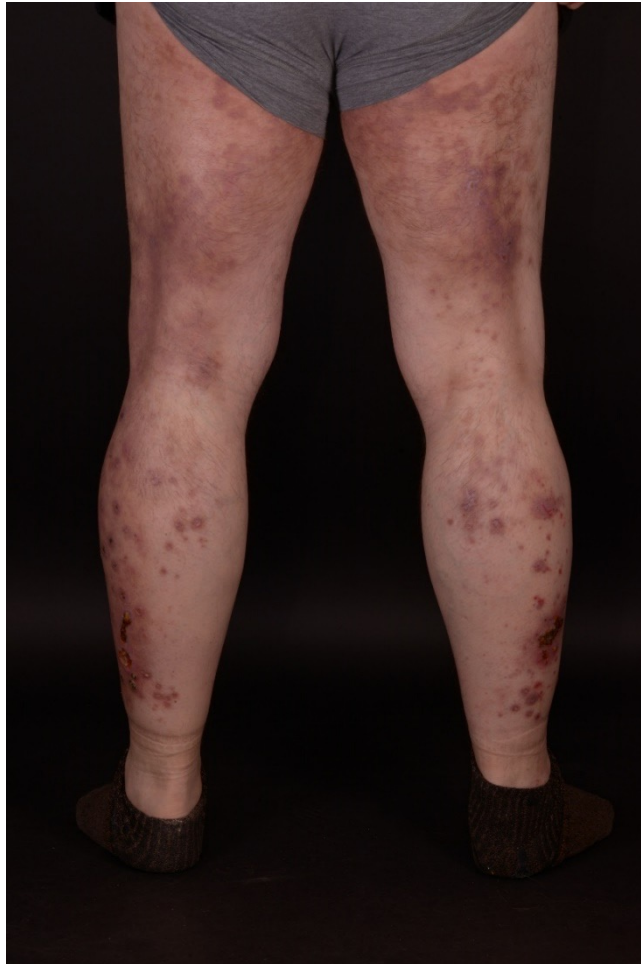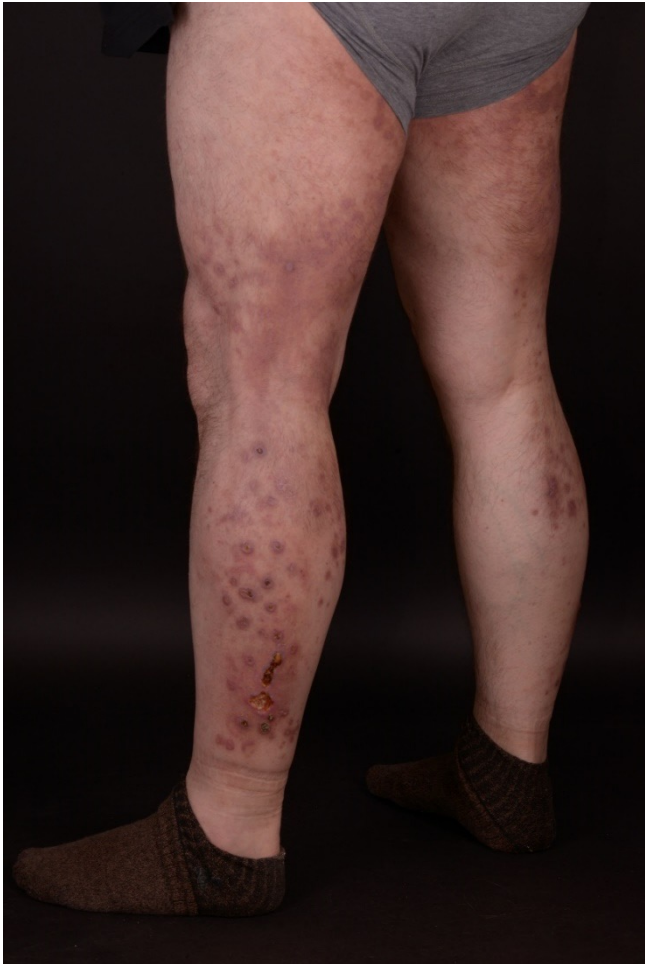The Diabetic Foot

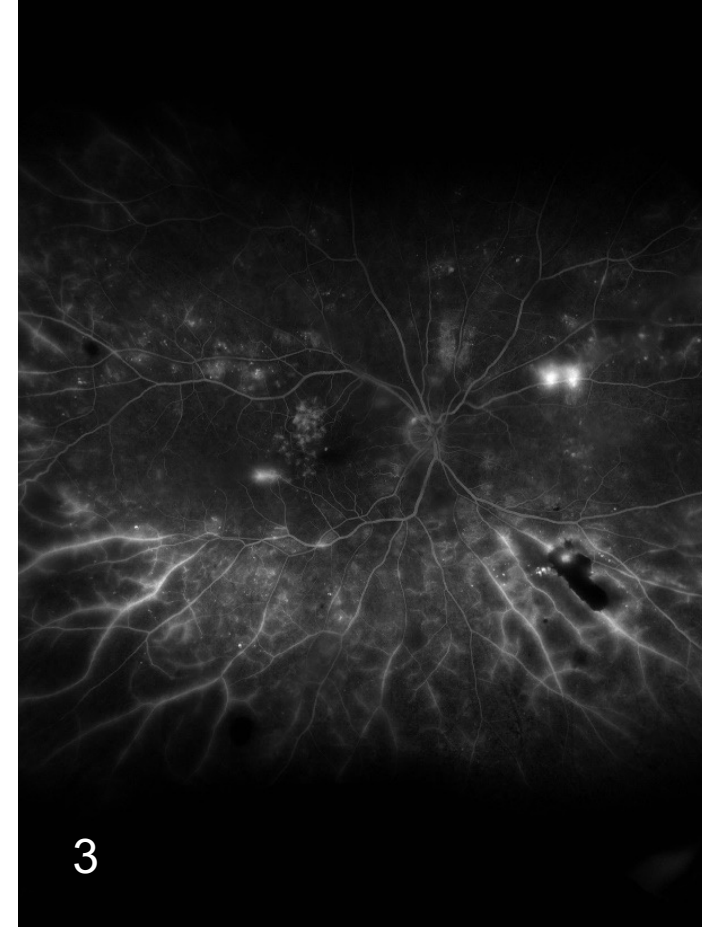
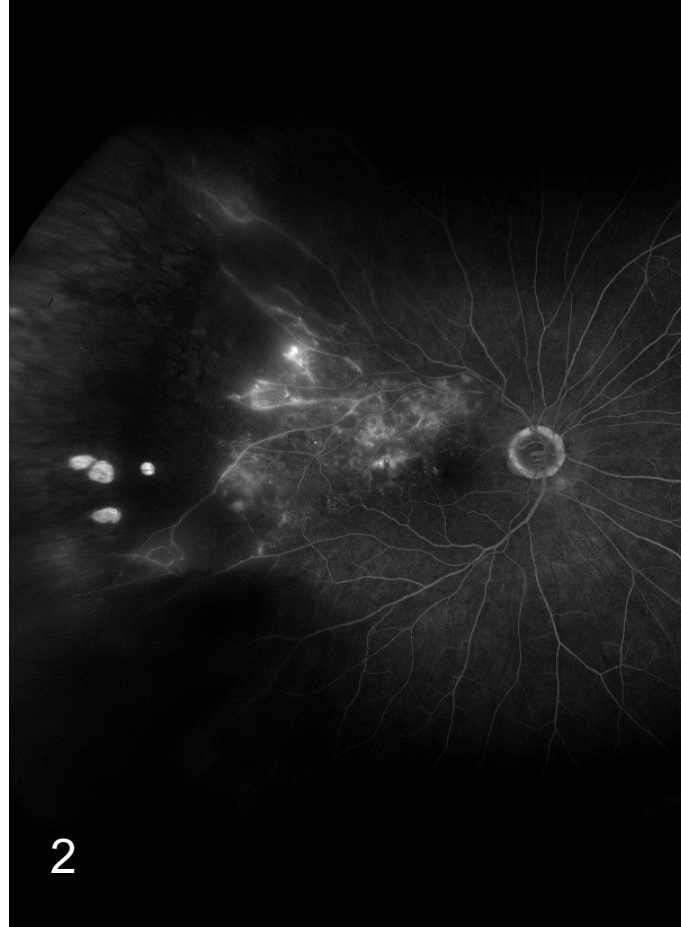
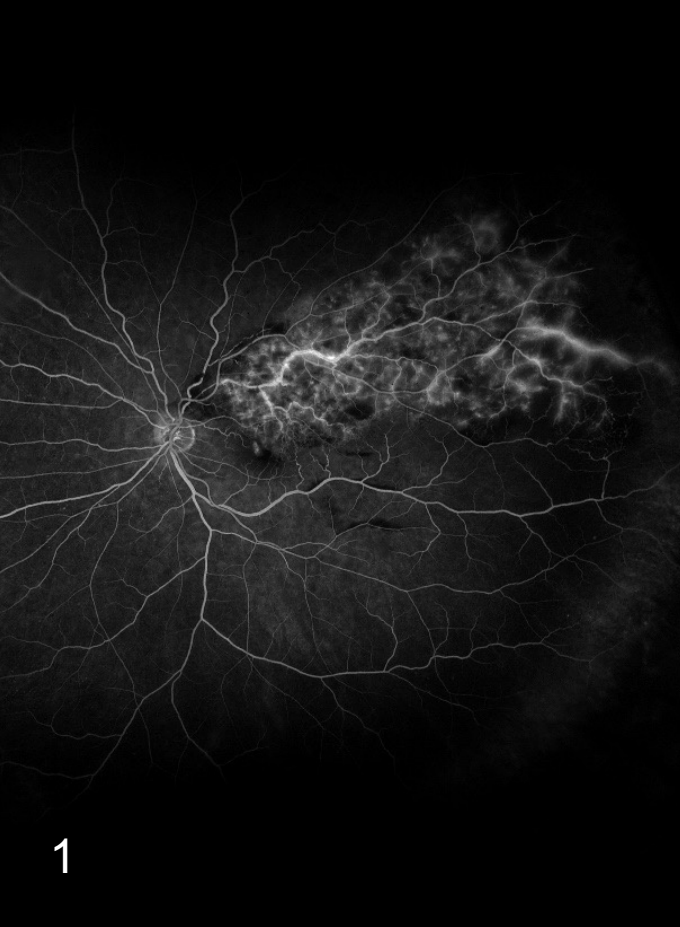- 51 yr male
- 21 yr known history of type 2
- 22nd Dec



Skin Problems


- 59 yr male
- Poorly managed diabetes





How did you do?

1. Left branch retinal vein occlusion with cystoid macular oedema
2. Branch retinal vein occlusion
3. Diabetic retinopathy



Thank you!